

Inhibition of fibrous adhesion formation in the temporomandibular joint of tenascin-C knockout mice

Y. Shinohara, K. Okamoto, Y. Goh,
N. Kiga, I. Tojyo, S. Fujita

Department of Oral Maxillofacial Surgery,
Wakayama Medical University, Japan

Abstract

Tenascin-C (TNC) is a large hexameric extracellular matrix glycoprotein that is expressed in developing organs and tumors. It has been reported that TNC is expressed in inflamed synovial membranes and deformed discs of temporomandibular joint (TMJ) disorder. However, the role of TNC in TMJ is not fully known. In this study, the role of TNC in fibrous adhesion formation of TMJ was examined using TNC knockout (TNCKO) mice. Hypermobility was produced by excessive mouth opening method on the TMJ of both wild-type (WT) and TNCKO mice. TMJ wound healing was compared histologically, and the expression of TNC, fibronectin (FN), and α -smooth muscle actin (α -SMA) in the wounded TMJ was examined by immunohistochemical and immunoblot analyses. Based on histologic analysis, fibrous adhesions were observed in the TMJ of both TNCKO and wild-type (WT) mice after excessive mouth opening. However, fibrous adhesion formation in TNCKO mice occurred later than in WT mice. TNC was expressed in the wounded TMJ disc and mandibular fossa. Although FN and α -SMA expression in the TMJ of TNCKO and WT mice was up-regulated after excessive mouth opening, FN and α -SMA protein levels were higher in WT mice at the same time points. In the wounded TMJ, TNC appears to enhance the expression of FN and α -SMA, and a lack of TNC may reduce fibrous adhesion formation in the TMJ. TNC plays an important role in TMJ wound healing, especially for wounds generated by mechanical stress.

Introduction

A broad spectrum of temporomandibular joint (TMJ) disorders (TMD) is recognized, ranging from an occasional painless click to degenerative diseases with condylar and mandibular fossa resorption. Adhesion formation is a degenerative change that plays a role in pain, as well as in the progression of disc

pathology by mechanical limitation of disc function.¹⁻³ Remodeling is an essential biological response to normal functional demands, homeostasis of joint structure, and function and occlusal relationships.⁴ Arnett *et al.* proposed an explanation for the pathophysiology of degenerative changes as one that results from dysfunctional articular remodeling due to excessive or sustained physical stress to the TMJ articular structures that exceeds the normal adaptive capacity.⁵ Increased loading in the TMJ may stimulate remodeling, involving increased synthesis of extracellular matrices.⁶ Microtrauma produced during mandibular movement, synovitis, or a masticatory muscle disorder may occasionally lead to unfavorable biomechanics of the TMJ complex, leading to excessive mechanical stress and resulting in adhesion formation. Adhesion formation is a process that can occur during wound healing, and is characterized by microtrauma-induced elevation of extracellular matrix synthesis.

Tenascin-C (TNC) is a disulfide-bonded hexameric matrix component composed of subunits with molecular weights in the range of 120-300 kDa.^{7,8} TNC is highly expressed during embryonic development, tissue repair, and in pathological conditions such as chronic inflammation. TNC interacts with several other extracellular matrix molecules and cell-surface receptors, thus affecting tissue architecture, tissue resilience, and cell responses.⁹ In TMJ tissues, immunolabeled TNC is present at low levels in normal healthy synovial membranes and discs, while it is up-regulated in the inflamed synovial membranes and deformed discs of TMD.¹⁰ TNC regulates cell differentiation, division, migration, binding, and regulatory processes during the formation of bone matrices in the mandibular condyle.¹¹ Although these previous studies strongly suggested that TNC is involved in TMD, it has not yet been determined whether TNC promotes fibrous adhesion formation in the TMJ. Fibronectin (FN) is a large, adhesive glycoprotein that is found in the extracellular matrix of a variety of tissues, including articular tissues of the TMJ.¹² Normal TMJ tissue weakly expresses FN, with more pronounced expression in TMD tissue.¹³ FN is composed of heterodimers connected by 2 disulfide bonds near their carboxyl ends. FN is a polyvalent molecule composed of several domains that contain binding sites for a large number of extracellular matrix components, such as collagen, heparin, and fibrin. FN molecules also contain domains that facilitate cell adhesion via cell surface receptors, called integrins.¹⁴ In an *in vitro* study, Dijkgraaf *et al.* demonstrated that FN may be involved in adhesion formation *via* free radical-mediated crosslinking.¹⁵ They observed that during elevated oxidative stress, fragments of FN form a high molecular weight

Correspondence: Dr. Yuji Shinohara, Department of Oral Maxillofacial Surgery, Wakayama Medical University, 811-1 Kimiidera, Wakayama 641-8509, Japan.
Tel/Fax: +81.73.441.0643.
E-mail: yuji@wakayama-med.ac.jp

Key words: Temporomandibular joint, excessive mouth opening, fibrous adhesion, tenascin-C, fibronectin, α -smooth muscle actin.

Acknowledgments: We are indebted to Prof. S. Saika and Y. Okada, Department of Ophthalmology, Wakayama Medical University for providing the TNCKO mice.

This work was partly supported by KAKENHI from the Ministry of Education, Culture, Sports, Science and Technology, and the Japanese Government.

Contributions: YS, SF, study design; YS, KO, YG, NK, IT, experimental procedures, immunohistochemical processing, microscopic analysis, data collection and/or preparation of figures; YS contributed especially to western blot analysis. All authors have reviewed and contributed to the different draft versions of the manuscript and have read and approved the final manuscript.

Conflicts of interest: the authors declare no conflicts of interests.

Received for publication: 29 October 2013.

Accepted for publication: 9 September 2014.

This work is licensed under a Creative Commons Attribution NonCommercial 3.0 License (CC BY-NC 3.0).

©Copyright Y. Shinohara *et al.*, 2014
Licensee PAGEPress, Italy
European Journal of Histochemistry 2014; 58:2337
doi:10.4081/ejh.2014.2337

aggregate. Therefore, the authors argued that these crosslinked proteins might serve as the initial scaffolding for the development of adhesions frequently seen in TMD.

The term myofibroblast was proposed for fibroblastic cells within granulation tissue that exhibited cytoplasmic microfilamentous apparatus.¹⁶⁻¹⁸ It was later discovered that the microfilament structure of myofibroblasts was α -smooth muscle actin (α -SMA), the actin isoform typical of smooth muscle cells in vessel walls that serves as a contractile smooth muscle protein; α -SMA is currently accepted the most reliable marker of myofibroblasts. Myofibroblasts have been seen in non-musculoskeletal pathologic fibrotic conditions characterized by contractures such as liver cirrhosis, pulmonary fibrosis, and corneal fibrosis.¹⁹⁻²¹

Several experimental animal models involving the use of a mandibular displacement appliance,²² alterations to the occlusion,²³ or tooth

extraction²⁴ have implicated the involvement of mechanical loading to the articular surface in histological changes of the TMJ, including the synovial membrane and the articular cartilage. Recently, a forced-jaw-opening protocol has been shown to be effective in inducing articular fibrous adhesions in the TMJ.^{25,26} These two studies are important since they clearly demonstrate that adverse joint loading without any surgical manipulation of the joint tissues can induce fibrous adhesion *in vivo*. TNC knockout (TNCKO) mice develop normally,²⁷ but exhibit abnormal behavior, defects in the structure and repair of neuromuscular junctions,²⁸ and defective recovery from snake venom-induced glomerulonephritis²⁹ and chemically induced dermatitis.³⁰ Moreover, it was reported that the absence of TNC suppresses the development of fibrosis in mice.³¹ The definite role of TNC in fibrous adhesions of the TMJ is not yet known. To elucidate this, we compared the wound healing process of the TMJ in TNCKO mice³² and congenic wild-type (WT) mice after excessive mouth opening. Furthermore, we investigated the expression of TNC, FN and α -SMA, which are important extracellular matrix proteins, in wound healing.

Materials and Methods

Animals and experimental protocol

Male TNCKO mice of the C57BL/6 strain and WT littermates (8 weeks of age) were used and maintained according to guidelines approved by the DNA Recombination Experiment Committee and the Animal Care and Use Committee of Wakayama Medical University. Excessive mouth opening was induced by opening the mouth widely (10 mm) under sodium pentobarbital anesthesia. This procedure was repeated 40 times, once daily for 20 consecutive days. Untreated (control) and treated mice were sacrificed after 1, 7, 12, or 20 days of the excessive mouth opening procedure. A total of 30 mice (15 TNCKO and 15 WT) were examined histologically, and additional 20 mice (10 TNCKO and 10 WT) were used for quantitative analyses.

Histochemical analysis

To compare histological changes as a result of TMJ loading by excessive mouth opening, histological analysis was performed. All mice were perfused via the left ventricle with 4% paraformaldehyde (PFA) under sodium pentobarbital anesthesia. TMJ samples were dissected out and fixed in a solution of 4% PFA for 24 h, and then washed for 24 h in phosphate-buffered saline (PBS, pH 7.4). Samples were decalcified in a 4% EDTA solution at 4°C for 4 weeks. The samples were dehydrated and

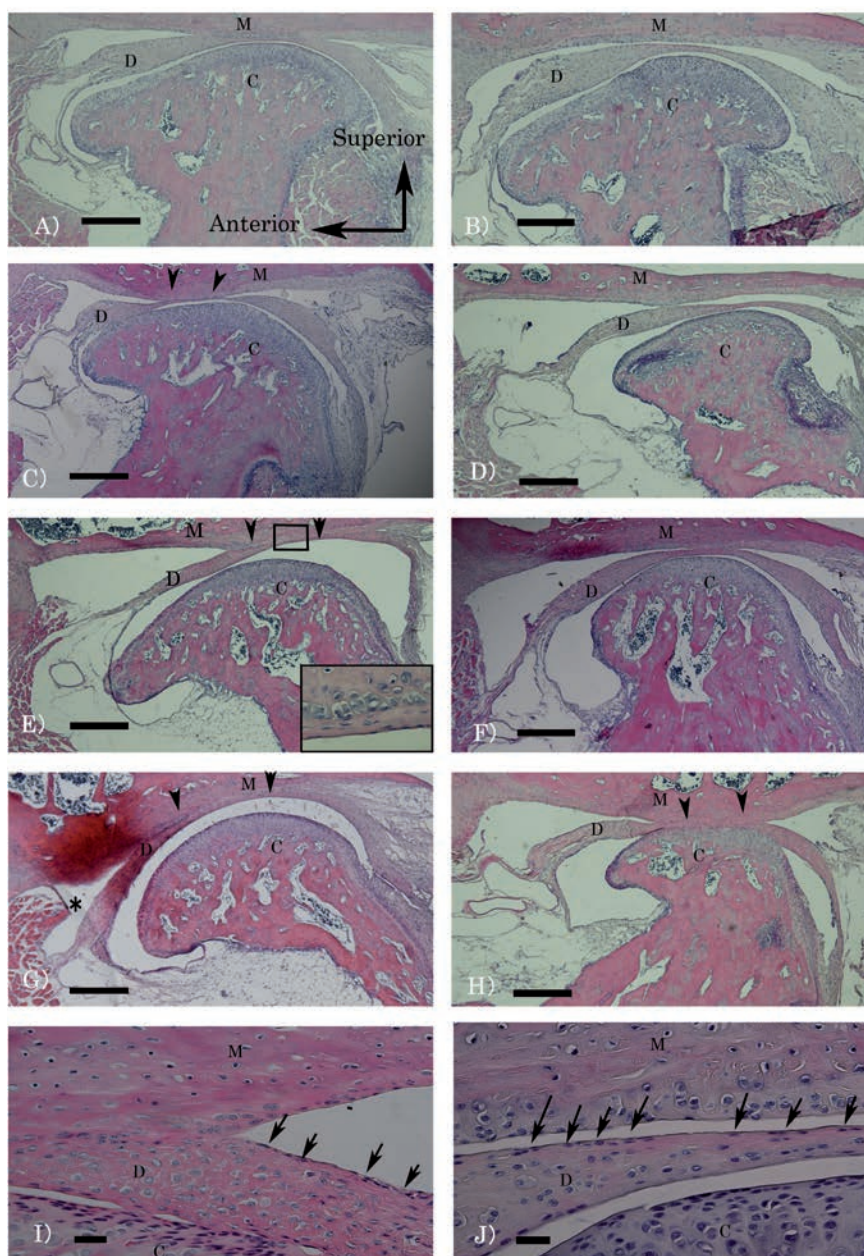


Figure 1. Hematoxylin-eosin staining of the TMJ of WT and TNCKO mice. Samples were collected after 1, 7, 12, and 20 days of excessive mouth opening. A), C), E), G), I) from WT mice. B), D), F), H), J) from TNCKO mice. At day 1, in both TNCKO and WT mice, no growth in the synovial membrane of the upper and lower cavities is observed (A, B). At day 7, fibrous adhesion could be seen in the upper cavity in WT mice (C), but not in TNCKO mice (D). At day 12, widespread fibrous adhesion formation is observed in the upper cavity in WT mice (E) and chondrocyte clustering was observed in the mandibular fossa (insert), while the disc of TNCKO mice remained slightly connected to the mandibular fossa (F). At day 20, the upper and anterior portions of the cavity were reduced in WT mice (G), but were unchanged in TNCKO mice (H). Fibroblasts on the articular disc surface disappeared in the area of fibrous adhesion (I). In control, continuous fibroblasts were observed on the articular disc surface (J). Arrows indicate fibroblasts on the disc surface. Arrow heads indicate fibrous adhesion area. M: Mandibular fossa. Asterisk: reduced upper cavity. D, disc; C, condyle. Scale bars: A-H) 200 μ m; I, J) 500 μ m.

embedded in paraffin. Subsequently, 4- μm -thick sections were stained with hematoxylin-eosin (HE). Histological photomicrographs were taken using a digital camera on a Nikon ECLIPSE E600 microscope equipped with a DS-L2 controller (Nikon Co. Ltd., Tokyo, Japan).

Immunohistochemical methods

Immunohistochemical staining was performed on paraffin sections. Endogenous peroxidase was blocked by immersing the sections in 0.3% H_2O_2 in methanol for 30 min at room temperature (RT). The specimens were blocked with 3% skim milk in 0.01% Tween-20-PBS for 60 min at RT and were then incubated overnight with a rat monoclonal primary antibody against TNC (1:100, Santa Cruz Biotechnology, Dallas, TX, USA), a rabbit polyclonal primary antibody against FN (1:200, Thermo Scientific, West Palm Beach, FL, USA) and a rabbit polyclonal primary antibody against α -SMA (1:200, GeneTex, Inc., Irvine, CA, USA). After washing with Tween-20-PBS, the specimens were treated with the appropriate secondary antibodies (polyclonal rabbit anti-rat immunoglobulins/HRP or polyclonal goat anti-rabbit immunoglobulins/HRP; Dako, Tokyo, Japan) for 60 min at RT. Color was developed using the Liquid DAB+Substrate Chromogen System (Dako) followed by counterstaining with Mayer's haematoxylin (Muto Pure Chemicals, Tokyo, Japan).

Western blot analysis

After an overdose of sodium pentobarbital, the right and left TMJ discs were carefully removed using a surgical microscope and washed with PBS. The samples were homogenized in Laemmli sample buffer (0.5 M Tris-HCl, pH 6.8, 10% SDS, 0.5% glycerol), centrifuged at 2000 g and the supernatants were collected. The samples (10 μg of protein) were electrophoresed on sodium dodecyl sulfate polyacrylamide (10%) slab gels and transferred onto nitrocellulose membranes (Invitrogen, Carlsbad, CA, USA). The membranes were incubated in 0.01% Tween-20-PBS containing 3% skim milk for 1 h at RT. Next, membranes were incubated with rat monoclonal antibody (1:400) against TNC (Abcam, Cambridge, MA, USA), goat polyclonal antibody (1:100) against FN (Santa Cruz Biotechnology) and rabbit polyclonal antibody (1:100) against α -SMA (GeneTex, Inc.) overnight at 4°C. The membranes were washed three times with Tween-20-PBS, and incubated with horseradish peroxidase-conjugated anti-rat IgG (1:100) and anti-goat IgG (1:100) (Dako). The proteins were visualized with ECL prime western blotting detection reagent (GE Healthcare, Stockholm, Sweden) following manufacturer's protocol.

Results

Histochemical analysis

The mouse TMJ is composed of the mandibular fossa, condyle and intervening articular disc, which divide the articular cavity into the upper and lower cavities. The disc of the mouse TMJ is a biconcave structure, composed of an intermediate zone and two bands and attachments. In the intermediate zone, a few spindle-shaped cells were scattered on the disc surface. The surface of the mandibular fossa was covered with a thin fibrous layer, and chondrocytes of the cartilage layer were observed under the fibrous layer. Also, the surface of the condyle was covered with cartilage tissue and a fibrous layer. There were no definite differences in the untreated articular structure between WT and TNCKO mice.

On day 1 post-treatment, contact between the disc and the mandibular fossa was observed in WT mice (Figure 1A), but not in TNCKO mice

(Figure 1B). In this contact area, some spindle-shaped cells were scattered on the disc surface. An upper cavity was seen between the mandibular fossa and the disc. No growths were observed in the synovial membrane of the upper and lower cavity in either WT or TNCKO mice. Fibrin deposits were not found on the surface of synovial membranes in either group. On day 7, fibrous adhesions could be seen in the upper cavity of WT mice (Figure 1C), but not in TNCKO mice (Figure 1D). In this adhesion area, some of the spindle-shaped cells disappeared from the disc surface (Figure 1I). However, fibroblast continuity was observed on the disc surface of TNCKO mice (Figure 1J). On day 12, widespread fibrous adhesion was observed in the upper cavity of WT mice (Figure 1E), and was observed to be longer than at day 7. The disc of TNCKO mice was in slight contact with the mandibular fossa (Figure 1F). At day 20, the upper and anterior portions of the cavity were reduced in WT mice (Figure 1G), but those of TNCKO mice remained unchanged (Figure 1H).

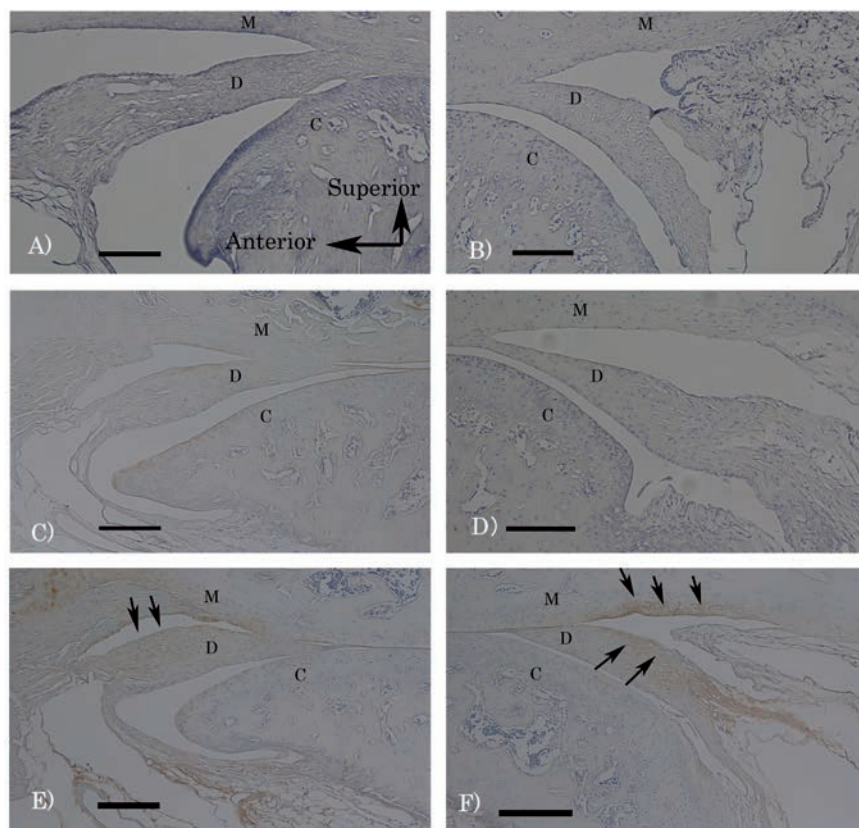


Figure 2. The expression of TNC in the TMJ of WT and TNCKO mice subjected to excessive mouth opening. TNC immunohistochemical staining of the TMJ (sagittal section) of TNCKO mice (A, B), and WT mice (C, D). The expression of TNC on the upper surface of the disc, condyle and mandibular fossa after excessive mouth opening was greater than in control mice (E, F). Arrows indicate expression of TNC. M, mandibular fossa; D, disc; C, condyle. Scale bars: 100 μm .

Immunohistochemical analysis of TNC, FN and α -SMA

Weak TNC expression was observed in the disc and the fibrous layer covering the condylar and mandibular fossa in control specimens of WT mice (Figure 2 C,D). However, TNC expression increased 1 day after excessive mouth opening. The upper part of the disc showed more intense TNC staining than the lower part in WT mice. TNC expression also increased in the mandibular fossa after excessive mouth opening in comparison with the control specimen of WT mice (Figure 2 E,F). No definite staining was observed in the TMJ of TNCKO mice (Figure 2 A,B). FN positive staining of the TMJ showed differences between WT and TNCKO mice. In the control specimen of WT mice, the surface of the disc and the fibrous layer on the mandibular fossa showed more intense FN staining than that of TNCKO mice (Figure 3 A-D). On day 1 after treatment, the WT sample showed intense FN staining at the disc and the fibrous layer on the mandibular fossa (Figure 3 E,F), whereas the TNCKO sample showed weak FN staining (Figure 3 G,H). α -SMA positive staining of the TMJ showed differences between WT and TNCKO mice. In the control specimen of WT mice, the disc and the fibrous layer on the mandibular fossa showed moderate α -SMA staining than that of TNCKO mice (Figure 4 A-D). On day 12 after treatment, the WT sample showed moderate α -SMA staining at the disc and the fibrous layer on the mandibular fossa (Figure 4 E,F), whereas the TNCKO sample showed weak FN staining (Figure 4 G,H).

Western blot analysis of TNC, FN and α -SMA

The western blot analysis of disc tissue revealed a single 230 kDa band for TNC expressed after treatment. TNC expression was very low in the control, but increased markedly after treatment from day 1 to day 20. Consistent with expectations, TNC was not detected in the TNCKO samples (Figure 5). The western blot results showed a single band of FN corresponding to a molecular weight of 220 kDa in WT and TNCKO samples (Figure 6). The expression of FN was very low in control, but increased markedly after treatment. The relative intensities of the FN bands were stronger in WT samples than in TNCKO samples. Additionally, the western blot results showed a single band of α -SMA corresponding to a molecular weight of 42 kDa in WT and TNCKO samples (Figure 7). The expression of α -SMA was moderate in control, but increased evidently at 12 days after treatment in WT sample. The relative intensities of the α -SMA bands were stronger in WT samples than in TNCKO samples at day 12 after treatment.

Discussion

The role of TNC in fibrous adhesion formation in the TMJ is not yet known. Trying to clarify this, we compared the TMJ wound healing process of WT and TNCKO mice after excessive mouth opening. In this study, we demonstrated that TNC promotes fibrous adhesion formation in the TMJ disc with excessive mouth opening. Furthermore, TNC appears to enhance the expression of FN and α -SMA, and a lack of TNC may reduce fibrous adhesion formation in the TMJ.

While the formation and pathogenesis of intra-articular adhesions in the human TMJ have not been fully clarified, Ronald *et al.* proposed the following explanation.¹ One of the theories claims that synovitis causes fibrin deposition, which decreases joint lubrication. The resultant suction cup effect and immobilization of the joint causes the fibrin deposition to continue, with the formation of fibrous adhesions. Another theory ascribes the formation of adhesions to hematomas in the synovial membrane that attract fibroblasts and fibrocytes to the area. The healing process is associated with the subsequent for-

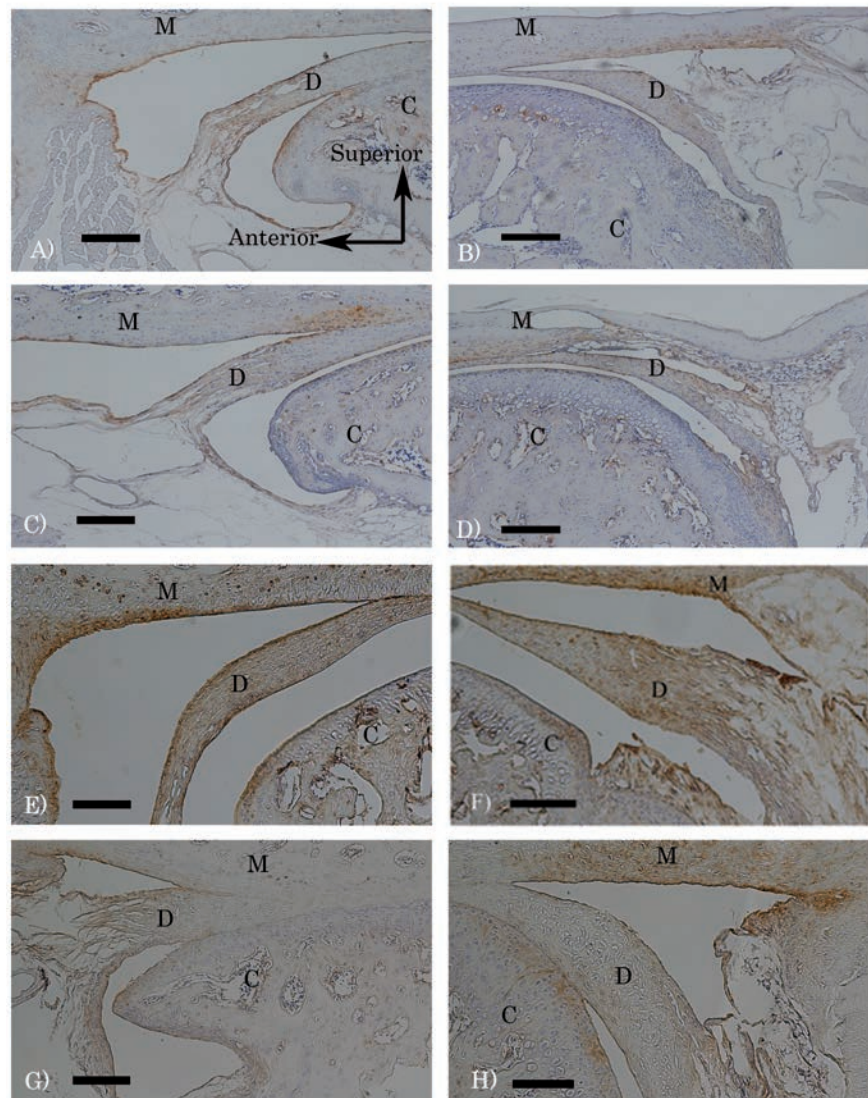


Figure 3. The expression of FN in the TMJ of WT and TNCKO mice subjected to excessive mouth opening. FN expression in the control TMJ of WT (A, B) and TNCKO mice (C, D). The surface of the disc and fibrous membrane of the mandibular fossa showed more intense FN staining in WT mice than in TNCKO mice. The TMJ sections at day 1 showed intense FN staining at the disc and the fibrous membrane on the mandibular fossa (E, F), whereas that of TNCKO mice showed a faint amount of FN staining (G, H). M, mandibular fossa; D, disc; C, condyle. Scale bars: 100 μ m.

mation of scar tissue on the existing fibrous capsular wall. In a previous report on the developmental and histological characteristics of synovitis, adhesions were induced in the synovium in the anterior portion of the cavity in the rat TMJ by excessive mouth opening.²⁵ However, detection of synovitis was based on increased synovial membrane and fibrin deposition; the existence of hematomas was not observed during our experimental period. In the current mouse study, the formation and progressive maturation of adhesions was induced between the mandibular fossa and the disc, instead of in the synovium, and was directly related to the duration of excessive mouth opening. These differences may depend on the extent of damage, length of treatment or anatomy of the animal species. Fibrous adhesion formation was initiated 7 days after the last treatment in the upper cavity and continued for 20 days in WT mice. The possibility exists that excessive mouth opening causes microtrauma due to excessive pressure on the disc by the hyper movement of the mandibular condyle and mandibular fossa. This microtrauma may cause the fibrin related adhesion, eventually developing into a fibrous adhesion. Fibroblasts, which exist in the fibrous layer of the mandibular fossa and disc, are thought to form collagen fibers and facilitate fibrous adhesion formation. Twelve days after the last treatment in WT mice, the extent of adhesion formation was increased with the clustering of chondrocytes in the cartilage layer of mandibular fossa (Figure 1E; see insert). Generally, chondrocyte clustering is a characteristic feature of the early stage repair process in the cartilage layer in osteoarthritis,^{33,34} and is a response that produces extracellular matrix components in the presence of mechanical stress on the chondrocytes. Throughout the experimental period, fibrous adhesions were not observed in the lower joint cavity. As this adhesion pattern resembles that of humans, excessive mouth opening is thought to cause mechanical stress in the upper part of the articular disc. On the other hand, initiation of fibrous adhesion formation in the disc of TNCKO mice was delayed in comparison to WT mice. Also, adhesion length did not increase throughout the experimental period, as was observed in WT mice. A reduction of the upper cavity area was not observed in TNCKO mice over the study period. In conclusion, while fibrous adhesions developed in WT mice, the fibrotic changes in TNCKO mice were clearly less extensive. These results indicate that TNC promotes fibrous adhesion formation in discs upon excessive mouth opening.

It is well known that FN is a major adhesive glycoprotein involved in wound healing and

its up-regulation is related to histological changes. Therefore, we compared the expression and changes in protein levels of TNC and FN in mice after induced hypermobility using immunohistochemical and western blotting analyses. Western blotting analysis showed dramatic increases in TNC and FN protein levels after excessive mouth opening in WT mice, which were maintained at a fixed level throughout the experimental period. Although the intensity of the FN band in TNCKO mice was extremely low in comparison to WT mice, mild up-regulation of FN protein was observed in TNCKO mice. TNC was expressed in the TMJ disc, mandibular fossa

and condyle 1 day after the last treatment in WT mice. TNC was more abundant near the upper surface of the disc than the lower surface. TNC was abundantly expressed on the mandibular fossa, indicating that it might correspond to TNC expression in the disc. TMJ is a dual diarthrodial joint; the upper compartment (mandibular fossa and disc) mainly functions as a sliding joint, while the lower compartment's (disc and condyle) rotational movement relates mainly to compressive force. During excessive mouth opening, the mandibular condyle and the mandibular fossa exert pressure on the TMJ disc. Mechanical loading induced up-regulation of

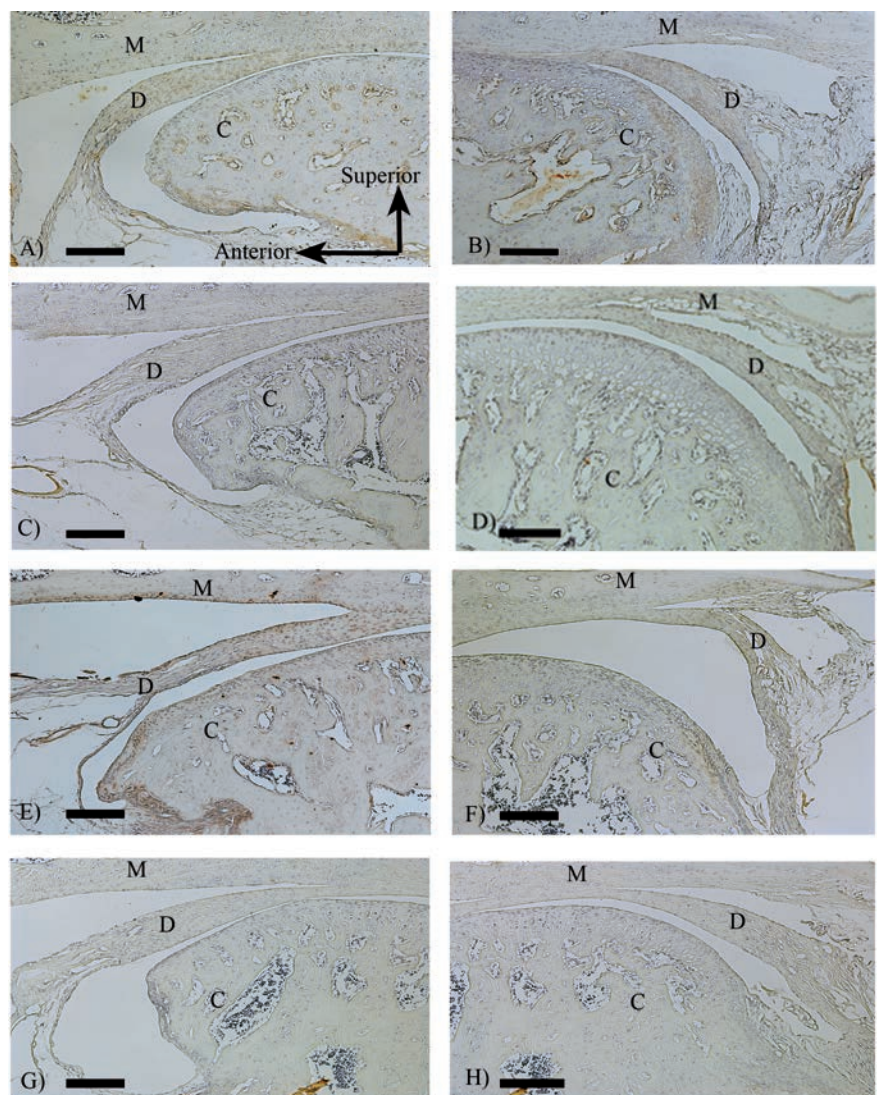


Figure 4. The expression of α -SMA in the TMJ of WT and TNCKO mice subjected to excessive mouth opening. α -SMA expression in the control TMJ of WT (A, B) and TNCKO mice (C, D). The TMJ sections at day 12 showed intense moderate α -SMA staining at the disc and the fibrous membrane on the mandibular fossa (E, F), whereas that of TNCKO mice showed a faint amount of α -SMA staining (G, H). M, mandibular fossa; D, disc; C, condyle. Scale bars: 100 μ m.

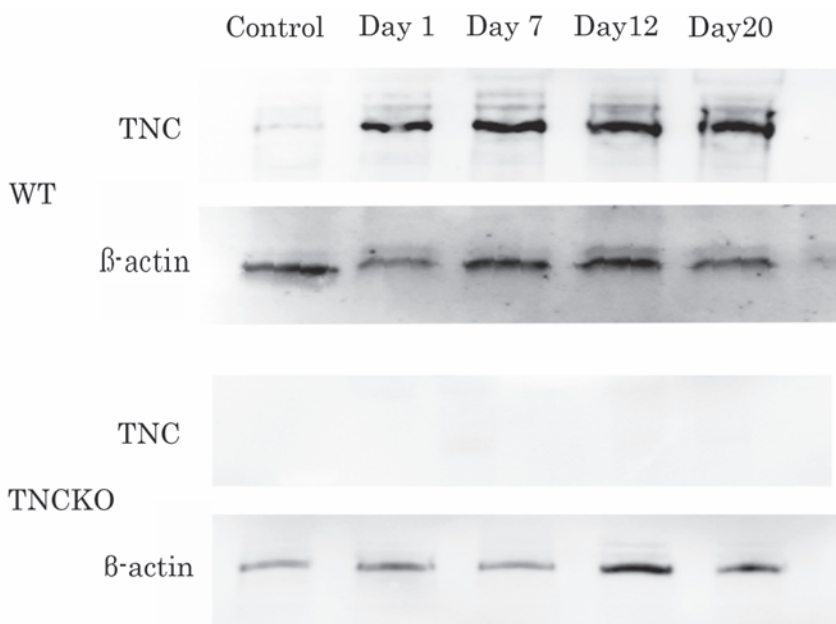


Figure 5. Chronological alterations in TNC expression in WT and TNCKO mice after excessive mouth opening. Western blot analysis showed a TNC band corresponding to 230 kDa in control, and day 1, 7, 12, and 20 samples from WT mice. However, a band corresponding to TNC was not detected in TNCKO samples. TNC expression increased after excessive mouth opening in WT samples.

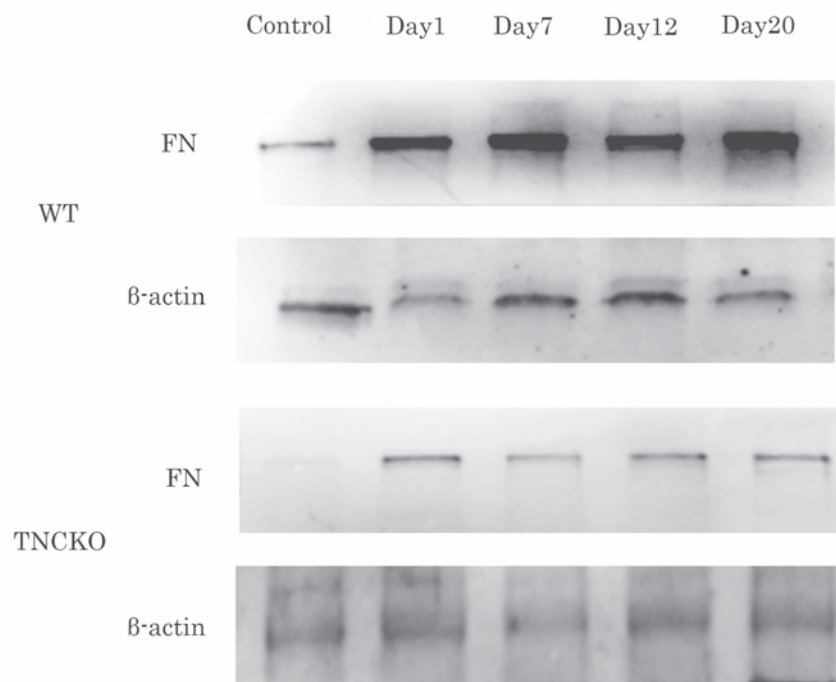


Figure 6. Chronological alterations in FN expression in WT and TNCKO mice after excessive mouth opening. Western blot analysis showed a FN band corresponding to 220 kDa in control, and day 1, 7, 12 and 20 samples from WT mice and TNCKO mice. Band intensity was stronger in WT samples than in the TNCKO sample at identical time points.

TNC expression. The expression pattern of FN in the superficial layer of the mandibular fossa and the disc was consistent with adhesion formation after treatment in both WT and TNCKO mice. Other studies have shown that the increase in tissue TNC levels can be used as a predictive marker for fibrosis.³⁵ TNCKO mice exhibit thinner stroma during corneal suture wounds with reduced FN deposition.³⁶ Similarly, lower levels of FN were detected in the granulation tissue during healing of dermal excisional wounds in TNCKO mice,³⁷ and only small and immature granulation tissue was observed during experimental kidney injury.²⁹ One reason for the delayed and decreased adhesion formation in the TMJ in TNCKO mice may depend on decreased FN protein levels.

Fibroblastic cells acquire contractile features during the healing of a wound, thus modulating into myofibroblasts which synthesize extracellular matrix components such as collagen type I and type III, and during normal wound healing disappear by apoptosis when epithelialization occurs. The transition from fibroblasts to myofibroblasts is influenced by mechanical stress.³⁸ Myofibroblasts are considered the main effector cell in joint fibrosis. One articular process (adhesive capsulitis of the shoulder) and two non-articular process (Dupuytren's contracture of the hand and hypertrophic scarring) have been shown to lead to non-traumatic contractures.³⁹⁻⁴¹ In both WT and TNCKO mice, the expression level of protein of α -SMA became maximum at 12 days after excessive mouth opening. The time α -SMA strongly expressed was in agreement with the time which the fibrous adhesion range expands. Therefore, α -SMA may be a factor related to formation of fibrous adhesion of mice disc. The intensity of the α -SMA expression in TNCKO mice was extremely low in comparison to WT mice. We consider the delayed and decreased adhesion formation in the TMJ in TNCKO mice may depend on decreased α -SMA protein levels. The expression of lumican, which is an extracellular matrix proteoglycan, increased in an inflammatory model using an articular disc cell line.⁴² Therefore, differences may exist in the expression of lumican in WT and TNCKO mice. Thus, it is thought that several genes participate in adhesion formation in TMJ. Further *in vitro* studies are needed to elucidate the mechanism by which TNC affects the expression of other extracellular matrix proteins.

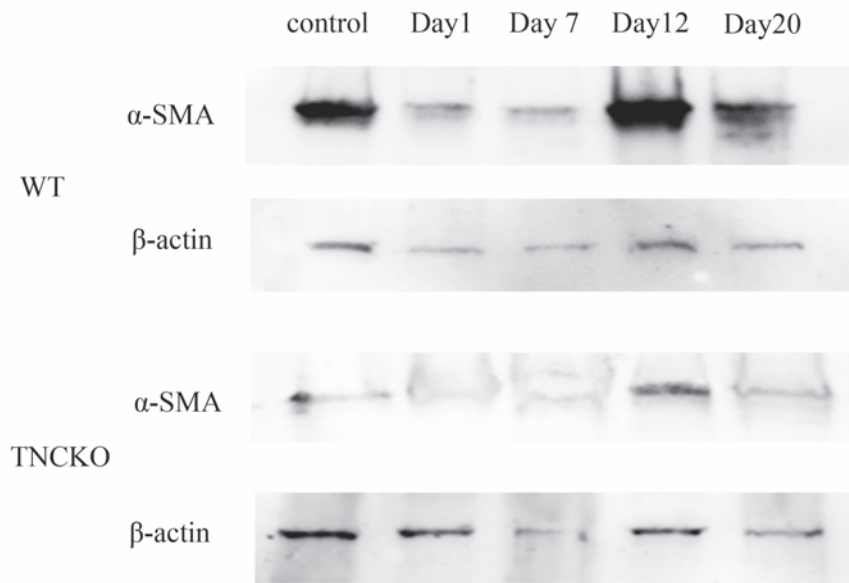


Figure 7. Chronological alterations in α -SMA expression in WT and TNCKO mice after excessive mouth opening. Western blot analysis showed a α -SMA band corresponding to 42 kDa in control, and day 1, 7, 12 and 20 samples from WT mice and TNCKO mice. Band intensity was stronger in WT samples than in the TNCKO sample at day 12 after treatment.

References

- Ronald M, Kaminishi RM, Davis CL. Temporomandibular joint arthroscopic observation of superior space adhesions. *Oral Maxillofac Surg Clin North Am.* 1989;1:103-9.
- Kurita K, Bronstein SL, Westesson PL, Sternby NH. Arthroscopic diagnosis of perforation and adhesions of the temporomandibular joint: Correlation with post-mortem morphology. *Oral Surg Oral Med Oral Pathol* 1989;68:130-4.
- Murakami K, Segami N, Moriya Y, Iizuka T. Correlation between pain and dysfunction and intra-articular adhesions in patients with internal derangement of the temporomandibular joint. *J Oral Maxillofac Surg* 1992;50:705-8.
- Smartt JM Jr, Low DW, Bartlett SP. The pediatric mandible: I. A primer on growth and development. *Plast Reconstr Surg* 2005;116:14-23e.
- Arnett GW, Milam SB, Gottesman L. Progressive mandibular retrusion--idiopathic condylar resorption. Part I. *Am J Orthod Dentofacial Orthop* 1996;110:8-15.
- Stegenga B, DeBont LGM, Boering G. Osteoarthritis as the cause of craniomandibular pain and dysfunction: a unifying concept. *J Oral Maxillofac Surg* 1989;47:249-56.
- Chiquet-Ehrismann R. Tenascins. *Int J Biochem Cell Biol* 2004;36:986-90.
- Tucker RP, Chiquet-Ehrismann R. The regulation of tenascin expression by tissue microenvironments. *Biochim Biophys Acta* 2009;1793:888-92.
- Midwood KS, Orend G. The role of tenascin-C in tissue injury and tumorigenesis. *J Cell Commun Signal* 2009;3:287-310.
- Tojyo I, Yamaguti A, Nitta T, Yoshida H, Fujita S, Yoshida T. Effect of hypoxia and interleukin-1 β on expression of tenascin-C in temporomandibular joint. *Oral Diseases* 2008;14:45-50.
- Sato I, Uneno R, Miwa Y, Sunohara M. Distribution of tenascin-C and tenascin-X, apoptotic and proliferating cells in postnatal soft-diet rat temporomandibular joint. *Ann Anat* 2006;188:127-36.
- Milam SB, Klebe RJ, Triplett RG, Herbert D. Characterization of the extracellular matrix of the primate temporomandibular joint. *J Oral Maxillofac Surg.* 1991;49:381-91.
- Leonardi R, Michelotti A, Farella M, Caltabiano R, Lanzafame S. Fibronectin upregulation in human temporomandibular joint discs with internal derangement. *J Craniofac Surg.* 2004;15:678-83.
- Milam SB, Haskin C, Zardeneta G, Chen D, Maqunson VL, Klebe RJ, et al. Cell adhesion proteins in oral biology. *Crit Rev Oral Biol Med.* 1991;2:451-91.
- Dijkgraaf LC, Zardeneta G, Cordewener FW, Liem RS, Schmitz JP, de Bont LG, et al. Crosslinking of fibrinogen and fibronectin by free radicals: a possible initial step in adhesion formation in osteoarthritis of the temporomandibular joint. *J Oral Maxillofac Surg* 2003;61:101-11.
- Serini G, Gabbiani G. Mechanisms of myofibroblast activity and phenotypic modulation. *Exp Cell Res* 1999; 250:273-283.
- Majno G, Gabbiani G, Hrschel BJ, Ryan GB, Statkov PR. Contraction of granulation tissue in vitro: similarity to smooth muscle. *Science* 1971;173:548-550.
- Gabbiani G, Majino G. Dupuytren's contracture: fibroblast contraction? An ultrastructural study. *Am J Pathol* 1972;66:131-46.
- Jester JV, Petroll WM, Cavanagh HD. Corneal stromal wound healing in refractive surgery: the role of myofibroblasts. *Prog Retin Eye Res* 1999;18:311-56.
- Serini G, Gabbiani G. Mechanisms of myofibroblast activity and phenotypic modulation. *Exp Cell Res* 1999;250:273-83.
- Tomasek JJ, Gabbiani G, Hinz B, Chaponnier C, Brown RA. Myofibroblasts and mechanoregulation of connective tissue remodeling. *Mol Cell Biol* 2002;3:349-63.
- Teramoto M, Kaneko S, Shibata S, Yanagishita M, Soma K. Effect of compressive forces on extracellular matrix in rat mandibular condylar cartilage. *J Bone Miner Metab* 2003;21:276-86.
- Honzawa O. [Effects of bite raising on fine structure of condylar cartilage in rats]. [Article in Japanese]. *Nihon Kyousei Shika Gakkai Zasshi* 1989;48:29-47.
- Endo Y, Mizutani H, Yasue K, Ueda M. Influence of food consistency and dental extractions on the rat mandibular condyle: a morphological, histological and immunohistochemical study. *J Craniomaxillofac Surg* 1998;26:185-90.
- Muto T, Kawakami J, Kanazawa M, Kaku T, Yajima T. Development and histologic characteristics of synovitis induced by trauma in the rat temporomandibular joint. *Int J Oral Maxillofac Surg* 1998;27:470-5.
- Siga T, Ishibashi K, Toyoda N, Nogami N, Ishii H, Ohtake M, et al. A production of experimental fibrous adhesions of the temporomandibular joint of the rabbit and its histological study. *J Jpn Soc TMJ* 2002;14:210-6.
- Saga Y, Yagi T, Ikawa Y, Sakakura T, Aizawa S. Mice develop normally without tenascin. *Genes Dev* 1992;6:1821-31.
- Cifuentes-Diaz C, Velasco E, Meunier FA, Goudon D, Belkadi L, Faille L, et al. The peripheral nerve and the neuromuscular junction are affected in the tenascin-C-deficient mouse. *Cell Mol Biol* 1998;44: 357-79.
- Nakao N, Hiraiwa N, Yoshiki A, Ike F, Kusakabe M. Tenascin-C promotes healing of Habu-snake venom-induced glomerulonephritis: studies in knockout congenic mice and in culture. *Am J Pathol*

- 1998;152:1237-45.
30. Koyama Y, Kusubata M, Yoshiki A, Hiraiwa N, Ohashi T, Irie S, et al. Effect of tenascin-C deficiency on chemically induced dermatitis in the mouse. *J Invest Dermatol* 1998;111:930-5.
31. El-Karef A, Yoshida T, Gabazza EC, Nishioka T, Inada H, Sakakura T, et al. Deficiency of tenascin-C attenuates liver fibrosis in immune-mediated chronic hepatitis in mice. *J Pathol* 2007;211:86-94.
32. Imanaka-Yoshida K, Matsumoto K, Hara M, Sakakura T, Yoshida T. The dynamic expression of tenascin-C and tenascin-X during early heart development in the mouse. *Differentiation* 2003;71:291-8.
33. Fujii K, Kuboki Y, Sasaki S. Aging of human bone and articular cartilage collagen: changes in the reducible cross-links and their precursors. *Gerontology* 1976;22:363-70.
34. Mankin HJ. The response of articular cartilage to mechanical injury. *J Bone Joint Surg Am* 1982;64:460-6.
35. Leiber CS, Weiss DG, Paronetto F. Value of fibrosis markers for staging liver fibrosis in patients with precirrhotic alcoholic liver disease. *Alcohol Clin Exp Res* 2008;32:1031-9.
36. Mastuda A, Yoshiki A, Tagawa Y, Matuda H, Kusakabe M. Corneal wound healing in tenascin knockout mouse. *Invest Ophthalmol Vis Sci* 1999;40:1071-80.
37. Forsberg E, Hirsch E, Fröhlich L, Meyer M, Ekblom P, Aszodi A, et al. Skin wounds and severed nerves heal normally in mice lacking tenascin-C. *Proc Natl Acad Sci USA* 1996;93:6594-9.
38. Gabbiani G. The myofibroblast in wound healing and fibrocontractive disease. *J Pathol* 2003;200:500-3.
39. Berndt A, Kosmehl H, Katenkamp D, Tauchmann V. Appearance of the myofibroblastic phenotype in Dupuytren's disease is associated with a fibronectin, laminin, collagen type IV and tenascin extracellular matrix. *Pathobiology* 1994;62:55-8.
40. Rodeo SA, Hannafin JA, Tom J, Warren RF, Wickiewicz TL. Immunolocalization of cytokines and their receptors in adhesive capsulitis of the shoulder. *J Orthop Res* 1997;15:427-36.
41. Nedelec B, Shankowsky H, Scott PG, Ghahary A, Tredget EE. Myofibroblasts and apoptosis in human hypertrophic scars: the effect of interferon-alpha 2b. *Surgery* 2001;130:798-808.
42. Kiga N, Tojyo I, Matsumoto T, Hiraishi Y, Shinohara Y, Makino S, et al. Expression of lumican and fibromodulin following interleukin-1 beta stimulation of disc cells of the human temporomandibular joint. *Eur J Histochem* 2011;55:e11.